



PATIENT

Franklin Seiden

SPECIES

Canine

BREED

Cavalier

SEX

Male Neutered

PRESENTING CLINICAL SIGNS

History: Heart murmur diagnosed 1 year ago. Progressive respiratory issues.
 -Radiographs: Cardiomegaly and pulmonary edema.
 -Current medications: Lasix 25mg IM

ECHOCARDIOGRAM FINDINGS

2D, m-mode, color flow and doppler imaging is available. Diffuse thickening of mitral valve leaflets with minimal prolapse into the left atrial lumen. Severe eccentric mitral regurgitation with severe left atrial dilation. Normal MR velocity. Mild LV dilation with hyperdynamic myocardial function. The tricuspid valve appears normal, with mild TR. Mildly elevated velocity. Normal right atrial and ventricular diameter and morphology. The pulmonic and aortic valves are normal in morphology and mobility. Normal aortic and pulmonic outflow velocities with laminar flow. No AI and trivial PI. No pericardial or pleural effusion noted. No obvious cardiac masses.

CARDIAC CHART

AGE

5.5 years

WEIGHT

NP

INTERPRETED BY

Maggie Machen Lamy,
 DVM, DACVIM
 (Cardiology)

IMAGING PERFORMED BY

Shari Reffi, CVT

HOSPITAL NAME

Berkeley Heights
 Animal Hospital

REFERRING VET

Dr. Lind

INVOICE

29942

DATE

3/30/23

CANINE CARDIAC PARAMETERS	MR VMAX (m/s)	TR VMAX (m/s)	LA/AO (Boon method)	LA/AO (Heart Base; Swe)	FS (%)	EF (%)	EPSS (cm)	
NORMAL PARAMETER	4.5-5.5	<2.7	1.3	<1.6	28-40	40-100	<0.6	
PATIENT	4.9	3.0	2.2	2.3	34	64	NM	
CANINE CARDIAC PARAMETERS	HR (BPM)	AV VMAX (m/s)	PV MAX (m/s)	BODY WEIGHT (kg)	LA 2D short axis Base view (cm)	LVIDd Avg; 2D and m-mode short axis (cm)	LVIDs Avg; 2D and m-mode short axis (cm)	
NORMAL PARAMETER	50-100	0.7-1.7	0.7-1.6	BELOW	BELOW	BELOW	BELOW	
PATIENT	160	0.9	0.6	NP	3.5	4.2	2.7	
*Normal chamber parameters expressed as a mean value (SD)					3	1.27 (5.3)	2.46 (2.46)	1.36 (5.5)
BODY WEIGHT DEPENDENT PARAMETERS					5	1.40 (4.5)	2.74 (5.2)	1.60 (4.7)
<i>*Note: All measurements based upon multi-modal images and methods. An average value is reported.</i>					10	1.50 (3.8)	3.27 (3.5)	2.06 (3.1)
					15	1.83 (2.0)	3.71 (2.4)	2.43 (2.1)
					20	2.02 (1.9)	4.14 (2.2)	2.80 (2.0)
					25	2.18 (2.4)	4.48 (2.9)	3.10 (2.5)
					30	2.33 (3.3)	4.83 (3.9)	3.39 (3.4)
					35	2.48 (4.3)	5.17 (5.0)	3.69 (4.5)
					40	2.62 (5.2)	5.48 (6.1)	3.96 (5.4)
					50	2.88 (7.1)	6.07 (8.3)	4.46 (7.4)

INTERPRETATION OF THE FINDINGS & FURTHER RECOMMENDATIONS

The cause of the murmur is chronic degenerative valve disease causing severe mitral and mild tricuspid regurgitation. Severe left atrial enlargement indicates the risk for spontaneous congestive heart failure is elevated. Early pulmonary hypertension is noted, which is likely secondary to chronic LA pressure elevation. No additional issues are identified.

In light of the clinical signs, chest radiograph findings and severity of disease on echocardiogram, the diagnosis is congestive heart failure and medications are warranted lifelong as below. Monitoring of sleeping respiratory rates will be paramount to screen for congestive heart failure at home. Cough suppression to improve QOL can also be considered (hydrocodone, 0.2-



PATIENT

Franklin Seiden

SPECIES

Canine

BREED

Cavalier

SEX

Male Neutered

AGE

5.5 years

WEIGHT

NP

INTERPRETED BY

Maggie Machen Lamy,
DVM, DACVIM
(Cardiology)

IMAGING PERFORMED BY

Shari Reffi, CVT

HOSPITAL NAME

Berkeley Heights
Animal Hospital

REFERRING VET

Dr. Lind

INVOICE

29942

DATE

3/30/23

0.4mg/kg up to q4-6h PRN) for any residual mechanical cough in the face of normal sleeping respiratory rates. The average survival time of canine patients with active pulmonary edema is 8-9 months on medications, however they generally are able to maintain a good quality of life for that period. Patient will always be at risk for recurrent CHF, development of arrhythmias/LA tear, syncope and/or sudden death in the future.

Omega fatty acid supplementation and mild salt restriction may also be of some long term benefit. Monitor for acute progression of the cough, labored breathing, exercise intolerance or collapse episodes in the future.

Elective anesthesia is not advised, as there is high risk for complication. Risk: benefit ratio should be considered. Consider consultation with and/or referral to a facility with an anesthesiologist. Should you elect to proceed, cardiac protective drug choices (opioid/benzodiazepine premedication, propofol or alfaxalone induction, iso or sevoflurane gas) are recommended. Pre-oxygenate for 5-10 minutes prior to induction and recover in O2 cage. Monitor for arrhythmias, hypotension, and hypoxia both intra and post-operatively and intervene as necessary. Moderate IV fluid restriction is recommended to avoid fluid overload, while considering comorbidities, hydration status, BP, etc. Avoid heart rate stimulating drugs such as atropine unless clinically indicated.

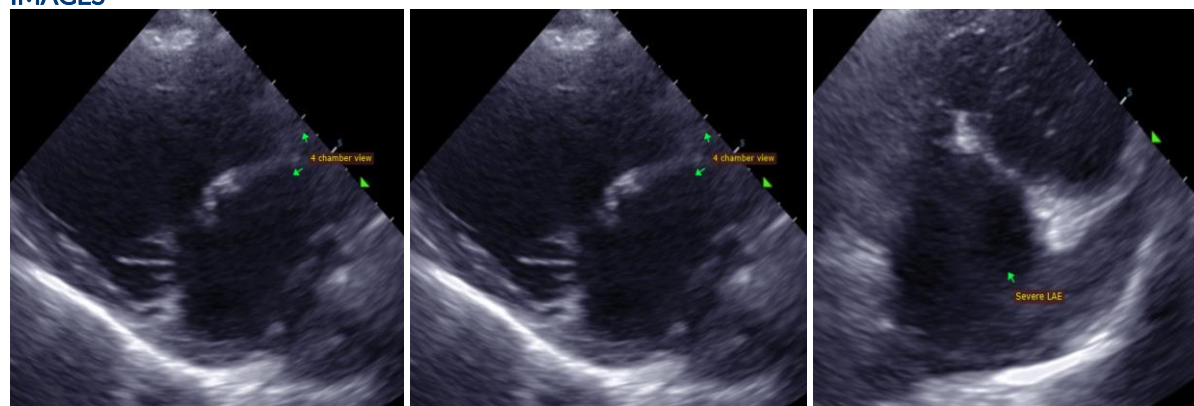
PLAN

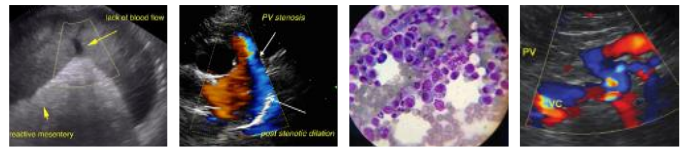
If the patient is or becomes unstable, hospitalization for injectable Lasix/O2 is recommended. Oral medications: Institute Pimobendan 0.3mg/kg PO q12h. Institute Furosemide 1-2mg/kg PO q12h. Institute spironolactone 1-2mg/kg PO q12h.

Monitor SRRs at home. Monitor renal values and BP in 10-14 days, then every 3-4 months while on diuretics. If doing well and BP >130mmHg, institute ACEI 0.5mg/kg PO q12h. Consider hydrocodone if needed for QOL.

Recommend conservative monitoring with a recheck echocardiogram in 6 months, sooner if any development of associated clinical signs occurs in the interim.

IMAGES





PATIENT

Franklin Seiden

The information and recommendations provided are based on the images presented by the referring veterinarian. No evaluation can be communicated regarding pathology that was not visible in the image/video clips provided.

SPECIES

Canine

Thank you for this referral. This report was generated using transcription software, and minor dictation errors may be present. If the clinical or image interpretation does not parallel your findings or if I can be of any further assistance, please contact me.

BREED

Cavalier

Maggie Machen Lamy, DVM
Diplomate of the American College of Veterinary Internal Medicine (Cardiology)
info@sonopath.com

SEX

Male Neutered

AGE

5.5 years

WEIGHT

NP

INTERPRETED BY

Maggie Machen Lamy,
DVM, DACVIM
(Cardiology)

**IMAGING
PERFORMED BY**

Shari Reffi, CVT

HOSPITAL NAME

Berkeley Heights
Animal Hospital

REFERRING VET

Dr. Lind

INVOICE

29942

DATE

3/30/23